

# Freehand Marking Technique for Mastopexy and Breast Reduction

Fahmy S. Fahmy

## 3.1 Introduction

Macromastia can cause considerable emotional and physical stress. The problem of macromastia has been the subject of the efforts of many plastic surgeons since late nineteenth century. In United States alone nearly 40,000 women undergo breast reduction each year [1].

Breast reduction presents both artistic and technical challenges. The surgery aims to reduce the vertical and horizontal planes, shape the parenchyma, reposition the nipple–areola complex, and resect redundant skin. The surgery on paired organs has the added challenge of symmetry. The added effect of recumbence alters the shape and position of the breast. The classic breast shape, as we know it, exists in the erect posture. Much of the outcome of our work as plastic surgeons is determined by preoperative planning and designing. The availability of numerous marking techniques of breast reduction and mastopexy and the abundance of further modifications over the last decennia are clear indications that none of these techniques have proved to be ideal.

The majority aim to achieve some degree of precision in determining the angle between the two vertical limbs. This ultimately affects the amount of tissue resected and the postoperative shape. Few, if any, of such techniques have gained total popularity or acceptance by the plastic surgeons. The freehand marking technique is probably the most widely used technique. Devices as templates [2, 3] shaped wires, goniometers, and geometrical techniques have also been recommended [4–9]. Some of these devices have stood the test of time; others have been modified or abandoned.

The free hand technique, being the most widely used, requires experience and practice in order to achieve the desired results. Multiple devices have been created to facilitate markings, including templates, keyhole patterns, goniometers, etc. The standard pattern with a fixed angle of 110° between the two segments was

further modified by McKissock [10] to allow for adjustment of the angle to the widely variable breast shapes. The wire keyhole pattern marking is influenced by the surgeon's experience [11].

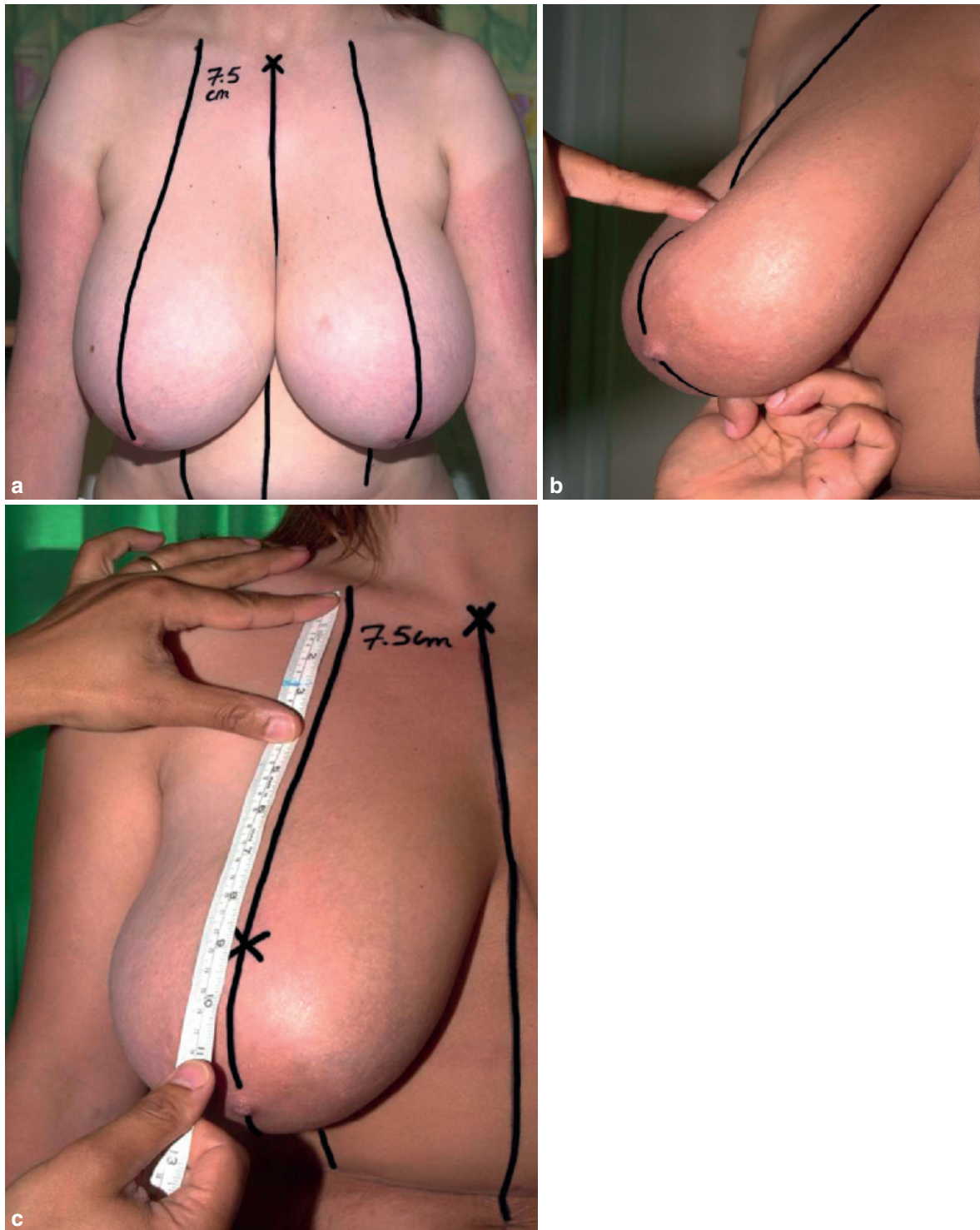
The standard patterns and devices are rigid methods that may achieve symmetrical markings, not necessarily symmetrical outcomes. They do not account easily to preexisting breast asymmetry. Devices may also be not readily available in all hospitals. This factor could be a disadvantage to the surgeon who practices in more than one hospital.

The inherent difficulties of these techniques, the lack of flexibility, and the need to memorize different measures and mathematical calculations on some occasions made me alter my approach in the preoperative marking. Over the last 15 years, I have developed the sitting, oblique, supine (SOS) marking technique. This method is dependent on the natural breast fall and is aimed to guide the required angle between the two vertical limbs, each breast on its individual merits. It would be applicable in most breast reduction and mastopexy surgery; however, it is used largely in the inferior pedicle technique.

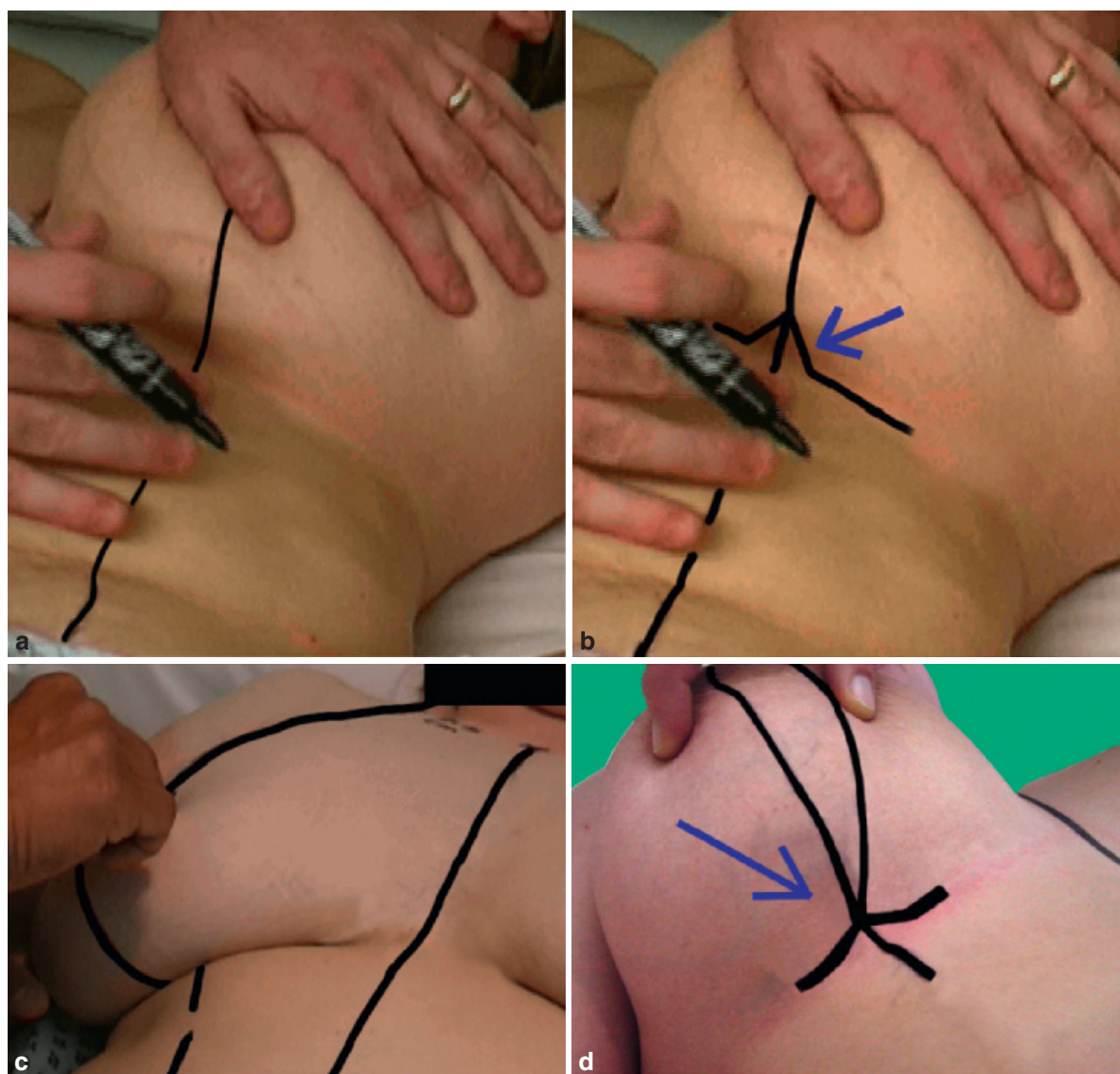
## 3.2 The SOS (Sitting, Oblique, Supine) Marking Technique

The patient is marked preoperatively in three positions.

1. *Sitting*: This position is adopted to mark the midline, midclavicular point (usually 7.5 cm from the sternal notch) and the breast meridian (Fig. 3.1). The breast meridian is marked as a straight line joining the midclavicular point to the current nipple–areolar complex (NAC) extending down to the inframammary fold. The superior limit of the vertical limbs is then marked with reference to the inframammary fold. This marks the possible future position of the NAC. The distance from the midclavicular point to the superior limit of the vertical limbs is then measured and the same measure is used to mark the contra-lateral NAC.



**Fig. 3.1** Patient in sitting position. (a) The breast meridian marked from the midclavicular point, usually 7.5 cm lateral to the sternal notch. (b) The superior limit of the vertical limb marked with reference to the inframammary fold. (c) The contralateral NAC is marked at the same distance from the midclavicular point

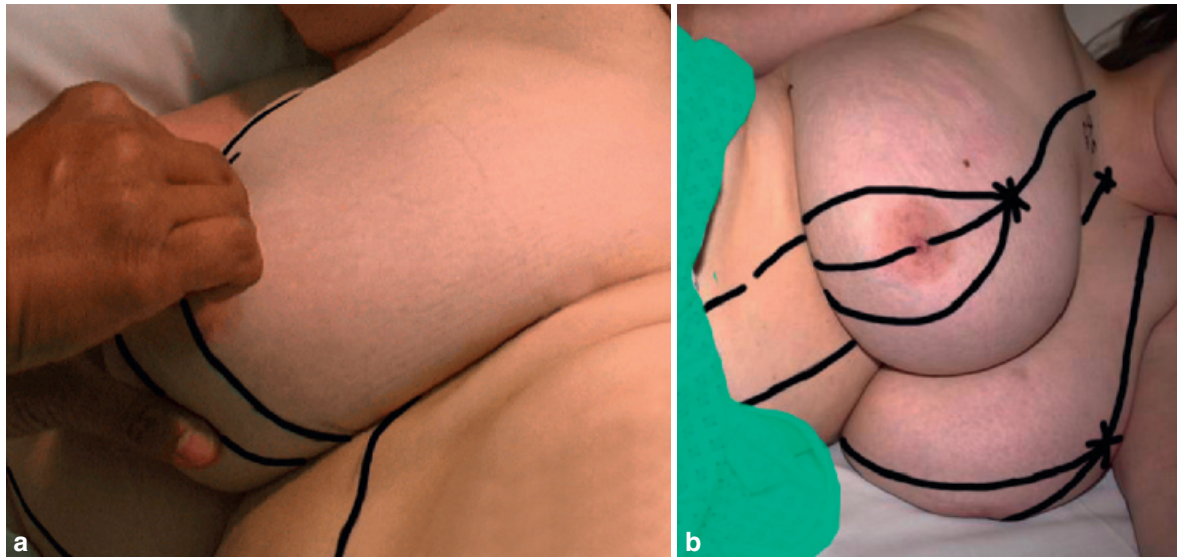


**Fig. 3.2** Patient in the supine position. (a) Gentle pressure on the breast mound clearly defines the inframammary fold. (b) Marking of the inframammary fold, arrow pointing to the dart. (c) Marking of the medial limb. (d) Marking of the medial limb completed

2. *Supine*: The supine position is used to mark the inframammary fold incision and the medial limb of the vertical markings (Fig. 3.2). While the patient is lying flat, the inframammary fold is marked with a very gentle pressure on the breast mound. Every effort should be made intra-operatively to minimize the length of the future inframammary scar. A “dart” coinciding with the breast meridian is marked along the inframammary incision line. This aids in reducing tension on the wound at the time of skin closure. While remaining in the supine position, the breast will naturally fall laterally. A straight line is drawn joining the superior limit of the vertical limbs to the

dart. This will indicate the medial limb of the vertical limbs.

3. *Oblique (Left and Right)*: The oblique position is mainly to mark the lateral limb of the vertical markings (Fig. 3.3). The patient is marked in the left and right oblique position. In the left oblique position, the right breast will naturally adopt a medial position. A straight line is marked joining the superior limit of the vertical limb to the dart. This marks the lateral limb of the right breast. While in the right oblique position, the left breast will adopt a medial position. A straight line is marked joining the superior limit of the vertical



**Fig. 3.3** Patient in the oblique position. (a) Right oblique position, marking the left lateral limb. (b) Left oblique position, right lateral limb marked

limbs to the dart. This marks the lateral limb of the left breast.

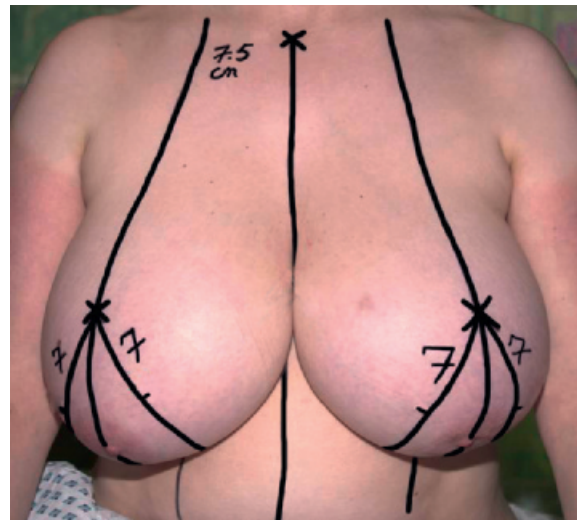
4. Finally, the patient is returned to the sitting position. The medial and lateral vertical limbs are measured at a length of 7 cm from the superior limit of the vertical limbs.

The above are all the required preoperative markings (Fig. 3.4). I now tend to join the vertical limbs to the medial and lateral ends of the inframammary marking intra-operatively. This is carried out in “a cut as you go” fashion aiming at avoiding dog-ears and also reducing the length of the inframammary scar. The new NAC is usually marked towards the end of the procedure, after the resection is completed.

The lower margin of the NAC is approximately 4–5 cm cephalad from the inframammary fold dart.

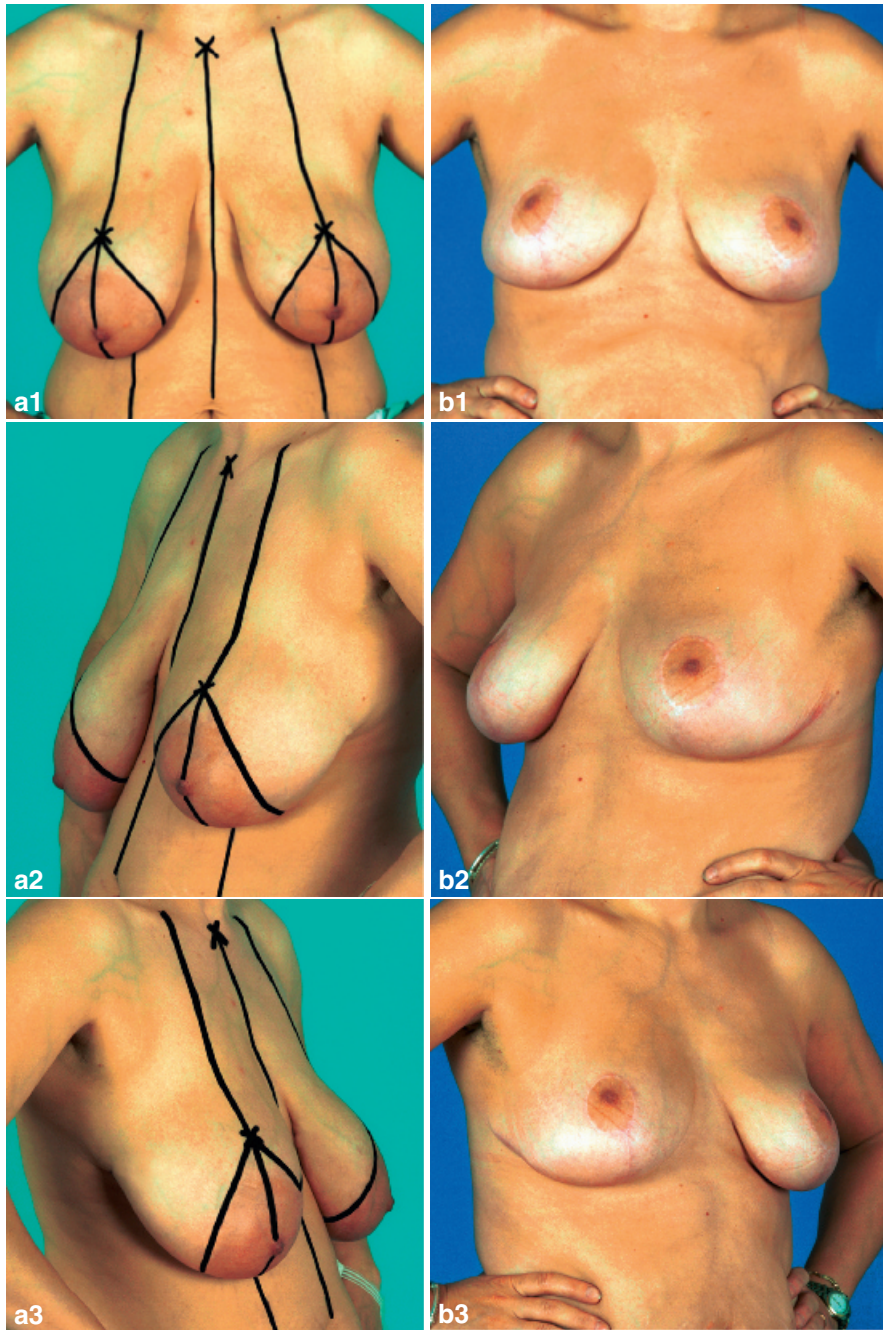
The SOS marking is a versatile technique dependent on the natural breast fall. The breast is viewed as a dynamic organ requiring the individual analysis of each breast (Fig. 3.5). The natural fall of the breast spontaneously generates the desired angle between the vertical limbs, accounting for any existing asymmetries (Fig. 3.6).

Marking the patient in the supine position has the added advantage of clearly identifying the inframam-

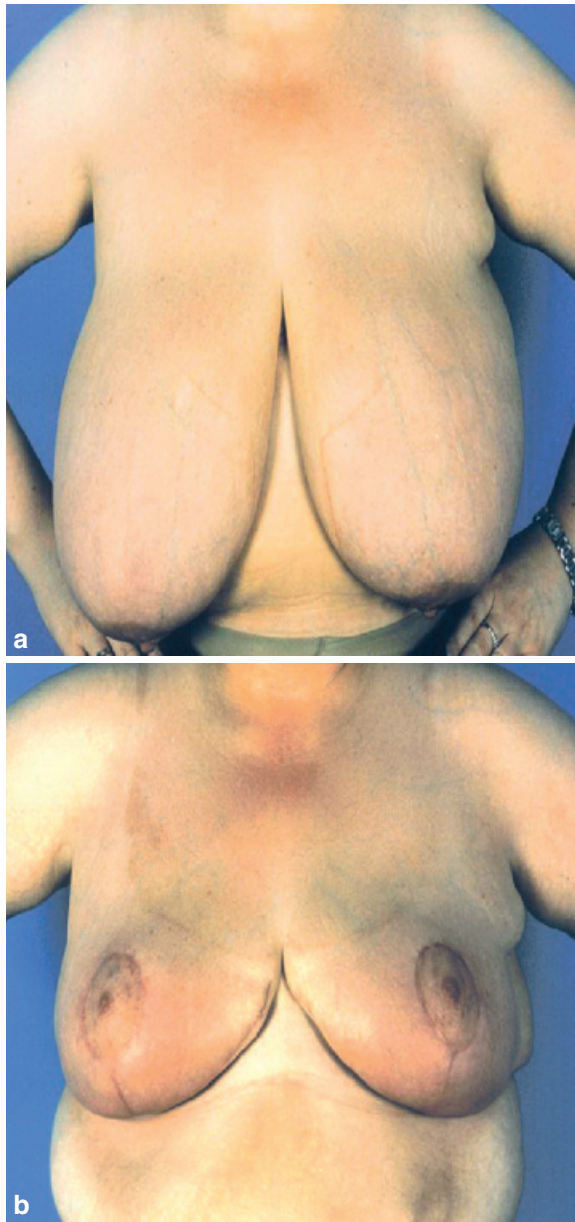


**Fig. 3.4** Patient in sitting position marking the length of the vertical limbs

mary fold. Marking in the sitting position only, as referred to in other techniques, may present difficulty in marking the inframammary fold in large ptotic breasts.



**Fig. 3.5** (a1-3) Preoperative. (b1-3) Six months postoperative



**Fig. 3.6** (a) Preoperative showing asymmetry. (b) Six months postoperative right breast reduction

There are no specific devices required in this technique. There is no need to memorize any particular reference points apart from the three standard land-

marks: the inframammary fold, the sternal notch, and the mid clavicular point. There is minimal handling of the breast, hence minimizing human errors.

Undoubtedly, there is a learning curve for any new technique. The SOS in my view is relatively easy to learn for the beginners and easy to adopt by the experienced. It is readily available, not requiring major alterations in our current practice and accounts for the great diversities in the shape and size of the breasts.

### References

1. Goldwyn RM, Courtiss EH: Reduction mammoplasty by the inferior pedicle (pyramidal) technique. In: Goldwyn RM (ed), *Reduction Mammoplasty*. Boston, Little, Brown & Co. 1990, pp 255–266
2. Wise RJ: A preliminary report on a method of planning the mammoplasty. *Plast Reconstr Surg* 1956;17(5): 367–375
3. Palumbo SK, Shifren J, Rhee C: Modifications of the Lejour vertical mammoplasty: analysis of results in 100 consecutive patients. *Ann Plast Surg* 1998;40(4): 354–359
4. Courtiss EH, Goldwyn RM: Reduction mammoplasty by the inferior pedicle technique. An alternative to free nipple and areolar grafting for severe macromastia or extreme ptosis. *Plast Reconstr Surg* 1977;59(4):500–507
5. Kavka S: A simple device for marking the areola in vertical mammoplasty. *Plast Reconstr Surg* 1999;103(7):2087
6. Mendez-Fernandez MA: An easy-to-make, easy-to-use device for preoperative marking for reduction mammoplasty and mastopexy. *Ann Plast Surg* 1991;26(6): 602–603
7. Lazarus D: A new template-goniometer for marking the wise keyhole pattern of reduction mammoplasty. *Plast Reconstr Surg* 1998;101(1):171–173
8. Beer GM, Morgenthaler W, Spicher I, Meyer VE: Modifications in vertical scar reduction. *Br J Plast Surg* 2001;54(4):341–347
9. Paloma V, Samper A, Sanz J: A simple device for marking the areola in Lejour's mammoplasty. *Plast Reconstr Surg* 1998;103(7):2134–2135
10. McKissock PK: Reduction mammoplasty by the vertical bipedicle flap technique. *Clin Plast Surg* 1976;3(2): 309–320
11. Gasperoni C, Salgarello M: Preoperative breast marking in reduction mammoplasty. *Ann Plast Surg* 1987;19(4): 306–311